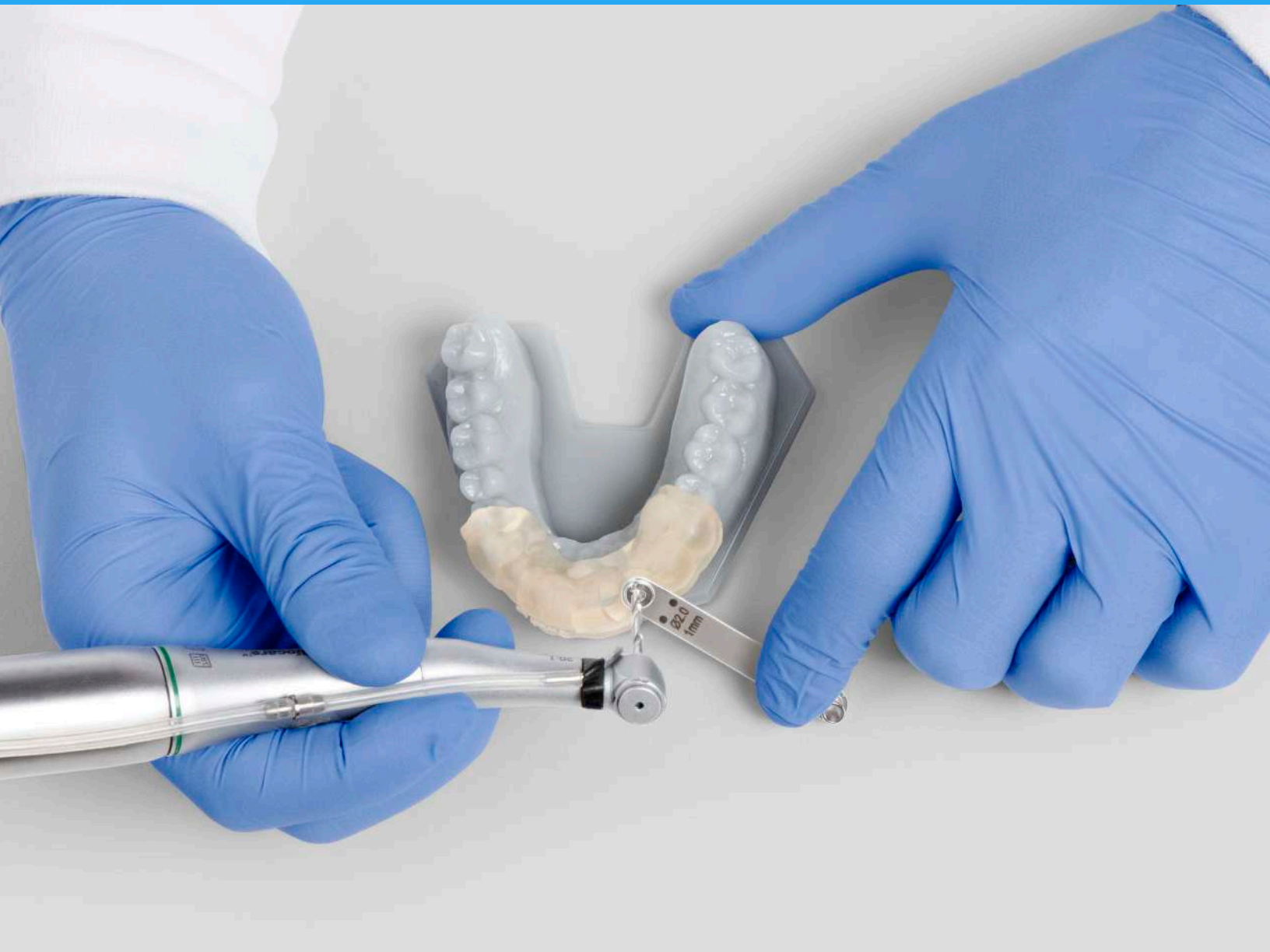



FORMLABS WHITE PAPER:

Digital Implantology with Desktop 3D Printing

Daniel Whitley, DDS

Sompop Bencharit, PhD, DDS, MS, FACP

formlabs.com

formlabs 



Table of Contents

Abstract	3
About the Authors	3
Introduction	4
Accuracy Study	6
Clinical Case	7
Discussion.	12
Conclusion	14
References	15

Abstract

Computer-aided implant planning and guided surgery provide high accuracy to dental implant placement and facilitate more predictable prosthetic outcomes than non-guided implant surgery. However, only a limited number of clinicians use guided surgery due to the high cost of current commercially available surgical guide fabrication systems. The protocol for using CAD/CAM surgical guide parts printed with biocompatible resin on a low-cost desktop 3D printer was investigated using Formlabs Dental SG Resin on the Form 2 desktop stereolithography (SLA) 3D printer. A clinical case using this protocol was carried out. The deviation between planned and final implant position was found to be clinically insignificant and well within the average accuracy of current industrial 3D printing solutions for dentistry. These results suggest that surgical guides can be accurately printed on the Form 2 and can be used to precisely place dental implants with acceptable clinical outcomes.

About the Authors

Daniel Whitley, DDS received his DDS from the University of North Carolina at Chapel Hill after earning his BS in Biology at North Carolina State University. He is a member of the American Dental Association, Academy of General Dentistry, North Carolina Dental Society, 5th District Dental Society and is on the executive committee for East Central Dental Society. He is a member of the ICOI and has specific areas of interest is CAD/CAM and digital dentistry and its applications to improving patient care. He is currently in private practice in Greenville, NC.

Dr. Sompop Bencharit, PhD, DDS, MS, FACP is a Diplomate of the American Board of Prosthodontics and a Fellow of the American College of Prosthodontists. He is one of a very few clinician-scientists who are both board-certified dental specialists and PhD scientists. Dr. Bencharit is a structural biologist specializing in protein X-ray crystallography. His research interests in structural biology focus on its applications in human diseases, in particular the role of signaling proteins involved in vessel and bone development, as well as disease-related salivary proteomics and microbiomics. He serves as an editorial board member or reviewer for numerous international scientific and dental journals, notably as Academic Editor for PLOS ONE and Editorial Board Member for Scientific Reports.

The authors would like to acknowledge Gideon Balloch, Meghan Maupin, Eric Arndt, PhD, and Timur Senguen, PhD, for their contributions to the paper. Photography by Rob Chron.

Introduction

Proper use of surgical guides can improve clinical outcomes in dental implant surgeries by facilitating detailed presurgical planning and precise placement of implant bodies. Definitive prosthetic design can be used during presurgical planning to determine the appropriate location for the osseointegrated implant, leveraging cone-beam computed tomography (CBCT) technology to evaluate osseous topography and identify vital structures¹. Guide use can help relieve clinicians of several perioperative decisions and reduce intraoperative time².

In addition, guide use results in significantly more precise implant placement than freehand techniques³. In implant surgery using freehand techniques, deviation between planned and actual implant position averages 2.0 – 2.5 mm, and ranges up to 8 mm⁴. Even for the most experienced surgeons, studies show that the final implant position deviates from the ideal position in the majority of freehand cases⁵. This can help to prevent a range of undesirable results, from iatrogenic injury to an unacceptable esthetic outcomes⁶.

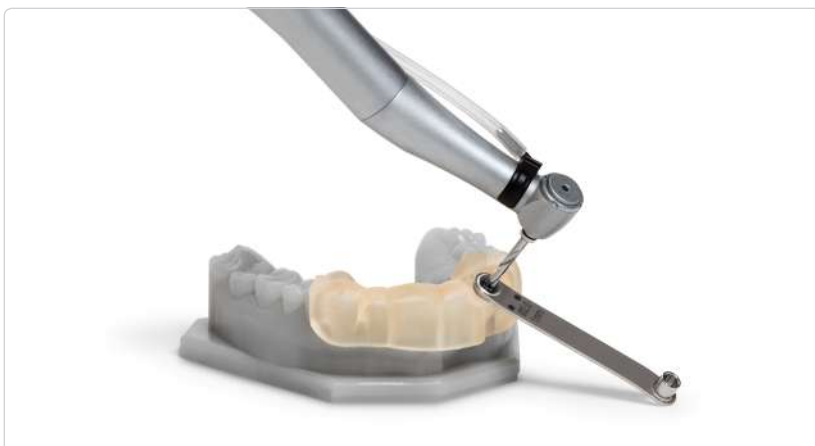As a result, various types of guides have been developed to direct the osteotomy and resultant placement of the implant body to the desired location⁷. The three main types of guide designs are (i) non-limiting guides, (ii) partially restricting guides, and (iii) completely limiting guides.

TYPES OF SURGICAL GUIDES

A **non-limiting guide** is the least precise design, providing a surgeon an idea of the desired prosthetic location, but not restricting drill angulation or depth. A **partially restricting guide** can help achieve slightly higher precision, as it fully directs the pilot drill but leaves subsequent drills to be freehanded based on the initial osteotomy.

A **completely limiting guide** fully restricts all drill angulations and

Fig. 1: CAD/CAM surgical guides fully restrict drill angulation and depth, and are designed using patient's CBCT scan data and intraoral optical scan data in implant planning software.



depth, and as a result is the most precise surgical guide type. Two common types of completely limiting guides are cast-based guides and computer-aided design/computer-assisted manufacturing (CAD/CAM) guides. **Cast-based surgical guides** are designed with bone sounding and periapical radiographs, using conventional analog manufacturing techniques such as thermoforming plastics on physical models⁷.

CAD/CAM guides are fabricated based on the patient's cone beam computed tomography (CBCT) data and a template of the desired final prosthetics⁷. Accurate optical scans of the patient's dentition can be incorporated after implant treatment planning.

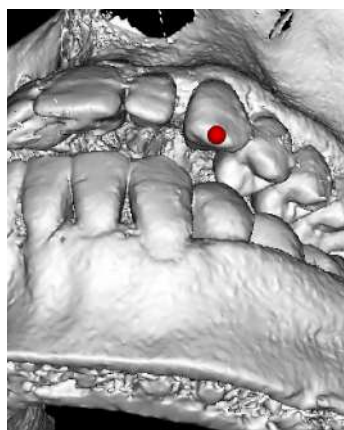
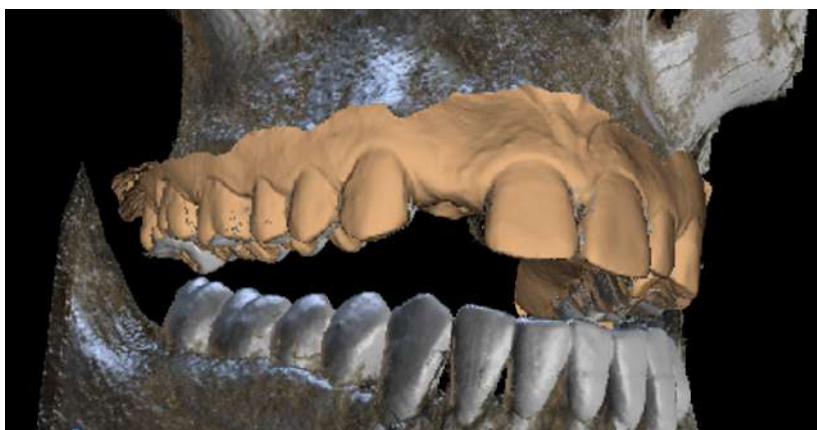

Fig 2: Combining CBCT and intraoral optical scan data facilitates detailed, accurate presurgical planning.



ADVANTAGES OF CAD/CAM SURGICAL GUIDES

CAD/CAM guides have been shown to achieve the highest level of accuracy in dental implant placement, significantly better than freehand techniques and also measurably better than cast-based guides. Implant surgery with cast-based surgical guides has been shown to achieve 1.5 mm average deviation in planned vs. actual implant position and 8° average deviation in planned vs. actual angulation². Comparatively, guided surgery with CAD/CAM guides can achieve precision consistently within 1 mm of the planned implant location at the entrance and 5° of the desired angulation⁴. Implant placement accuracy up to 0.1 mm has been shown to be achievable⁷.




In addition, the use of patient CBCT data in advanced implant planning software can reduce surgical time and improve clinical outcomes, by allowing for effective presurgical planning during the guide design process. This facilitates less invasive procedures and promotes optimal prosthetic outcomes¹. It also reduces the amount of intraoperative decision making that has to occur, allowing for easier, faster surgeries. Other benefits include conservation of anatomic structures and thorough examination of vital structures and osseous topography. Ultimately, this allows surgeons to carry out implant procedures with confidence.

Despite the significant benefits associated with the use of CAD/CAM guides, usage rates remain low. The high cost of additive manufacturing systems has limited the use of 3D printing technology to large commercial dental labs^{7,8}.

We set out to demonstrate that a desktop 3D printing system could (i) accurately print surgical guides and (ii) achieve acceptable clinical outcomes. A clinical case was used for the evaluation, which involved the Form 2 3D printer and Formlabs Dental SG biocompatible photopolymer resin.

Accuracy Study

ACCURACY OF PRINT TO 3D MODEL

-  ± 50 microns
-  ± 100 microns
-  ± 200 microns



CAD/CAM surgical guides must be produced within very tight dimensional tolerances in order to be useful in clinical applications. Assuming that the surgical guide model is well designed, when the model is sent to print, it is currently believed that a surgical guide will securely fit the patient's teeth or edentulous gums if 80% of its occlusal surface and surgical fixtures fall within a ± 100 micron range of the designed model. We set out to first verify that this milestone is achievable using Dental SG Resin on the Form 2, before validating fit quantitatively during the clinical study.

In an effort to verify that surgical guides printed on the Form 2 in the Dental SG Resin meet or exceed this standard, a set of 6 surgical guides (4 full arch guides and 2 quarter arch models) were printed several times on multiple printers. A total of 84 surgical guides were produced, cleaned, post-cured, removed from supports, and digitized using a 3Shape D900 orthodontic scanner.

Once scanned, each model was compared to its STL file, and a difference map was produced using Convince Analyzer (3Shape). Only the occlusal areas and surgical fixtures were included to ensure that only the relevant portions of the surgical guides were used in these calculations.

On average, $\sim 93\%$ of the occlusal surfaces and surgical features were measured to be within the desired ± 100 micron tolerance range, which clearly exceeds the desired standard. When including the standard deviation of these measurements ($\pm 5\%$), the 2σ interval of the distribution predicts that $\sim 95\%$ of surgical guides produced this way meet the ± 100 micron tolerance range. These findings suggest that using a Form 2 printer along with Dental SG Resin and the proper finishing technique will result in usable surgical guides for virtually every attempt.

Clinical Case

To empirically evaluate whether this level of print accuracy could achieve acceptable clinical outcomes, a clinical case was carried out.

HISTORY AND CLINICAL EXAMINATION

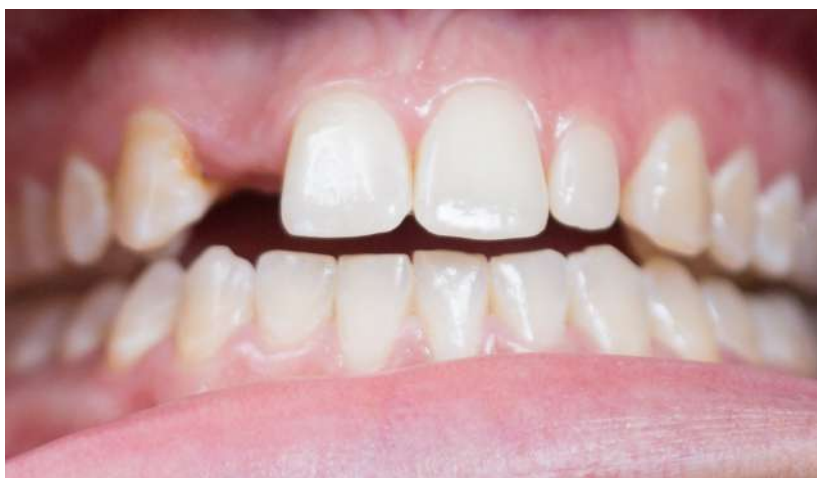A 26-year-old healthy female presented for a consultation with the chief complaint: “I want to do something more permanent to replace my missing tooth and fix the small tooth on the other side.” The patient presented with a congenitally missing #7 and a Bolton discrepancy in the #10 site. She has previously completed orthodontic treatment and presented with a bonded retainer on #8-9 to preserve space in the #7 site for an implant and a Hawley retainer with a pontic in the #7 site for temporary esthetic replacement of the tooth. A treatment plan for an implant in the #7 site, veneer on #10, ML composite on #6, and DL composite on #8 was developed and approved by the patient. We decided to place the implant first and treat the carious lesions while the implant was integrating.

PRETREATMENT: SMILE PLANNING, DIGITAL IMPRESSION TAKING, RADIOGRAPHIC EXAMINATION

Using smile design planning techniques, we determined the ideal dimensions for the patient’s lateral incisors, and a diagnostic wax-up was completed. A preoperative CBCT scan was taken using the Sirona Orthophos XG 3D (Sirona Dental; Bensheim, Germany). The patient’s jaws were positioned to have about 3 – 4 mm separation between the maxillary and mandibular occlusal surfaces to minimize the possible scattering effects from existing restorations.

Fig. 3: Pre-Operative Examination

Patient was congenitally missing #7 and wanted to permanently replace the missing tooth with an implant.



The CBCT scans were examined in Blue Sky Bio's implant treatment planning software, revealing a ridge of minimal bone thickness, ~5 – 6 mm at minimum. Without a drill guide, this would have been a very difficult procedure to complete predictably without the need for grafting. Instead, the use of a highly accurate 3D printed drill guide assured us that we could predictably perform this procedure.

INTEGRATION OF ANATOMICAL DATA, DETERMINATION OF IMPLANT POSITION & SURGICAL GUIDE DESIGN

A virtual implant was created to mimic the dimensions of a Zimmer Eztetic implant (Zimmer Eztetic 3.1 mm x 11.5 mm, Zimmer Biomet Dental, Palm Beach Gardens, FL) and a virtual tooth was designed to mimic the wax-up dimensions. We chose the Eztetic implant line from Zimmer Biomet Dental to preserve the maximum amount of facial bone in this thin ridge and to avoid the need for invasive and expensive grafting procedures while still achieving an optimal esthetic result.

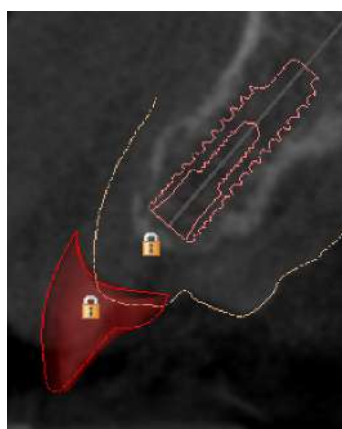
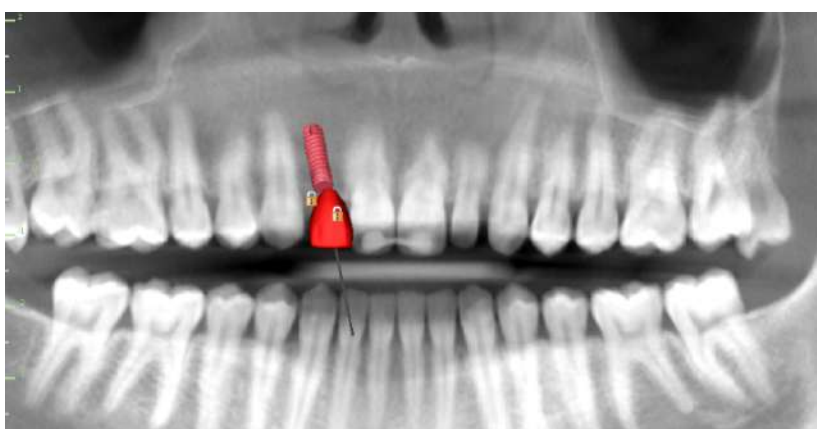
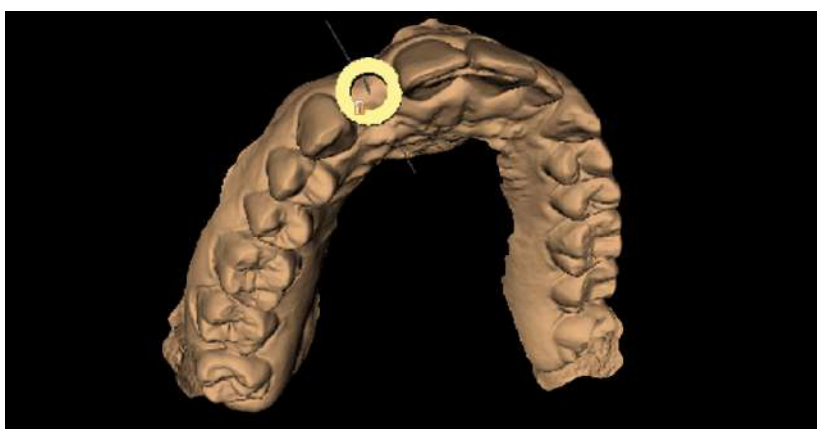


Fig. 4: CBCT scan examination in implant planning software revealed a ridge of minimal bone thickness, ~5 – 6 mm at minimum. Without a drill guide this would have been a very difficult procedure to complete predictably without the need for grafting.



Above: planning drill angulation and guide sleeve positioning during the surgical guide design phase. Below: Final visualization of the implant placement superimposed on the patient's CBCT data.

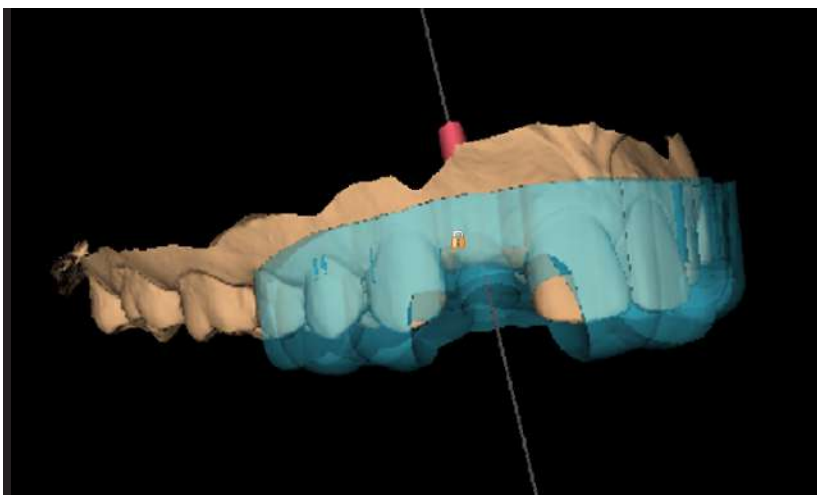
With the patient's anatomical data, virtual implant, and virtual restoration all integrated in the implant treatment planning software, we planned the implant treatment. The virtual implant was placed in an ideal position in relation to the wax-up and virtual tooth #7. A sextant guide was designed due to the ability to achieve optimal stability using the teeth mesial and distal to the edentulous area. The guide was designed using parameters that coincide with the Zimmer Guided Kit's 22 mm drills.

The dentition was optically scanned with the Cerec Omnicam (Sirona Dental; Bensheim, Germany). These files were then converted to .STL format through a local lab for integration into the software (Blue Sky Plan 3; Blue Sky Bio; Grayslake, IL, USA).

The highest-resolution .STL file was exported from the Blue Sky Bio software, which was the only point in time when a fee was incurred. This fee ranges from \$11 – \$20 depending on the user's purchase volume. Other implant planning software programs have differing fee structures.

GUIDE FABRICATION, ASSEMBLY AND STERILIZATION

The surgical guide .STL file was imported into PreForm, Formlabs' free software for preparing models for 3D printing. The guide was oriented in the software to minimize cross-sectional peeling forces during printing, allowing excess resin to drain. Support points were added only to non-occlusal surfaces to maintain the guide's accurate fit. Support points were carefully examined and manually removed from guide hole surfaces to enable easy post-processing and insertion of the metal drill sleeve. The resin volume used was 10.49 mL. The fully prepared .form file was then sent to the Form 2 and printed using Formlabs Dental SG Resin.

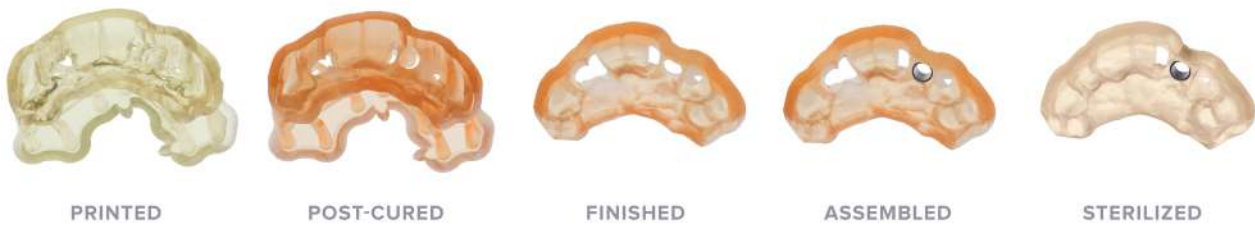


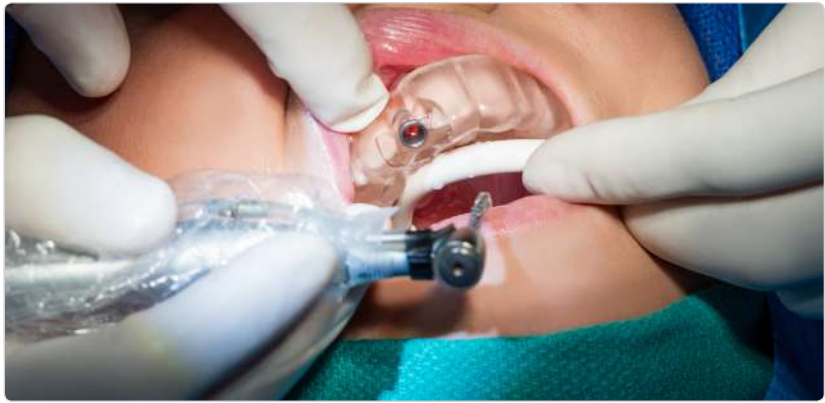Final guide design prior to model export.

After printing, the guide was removed from the build platform and rinsed in two baths of 91% isopropyl alcohol for a total of 20 minutes and then allowed to air dry. Next, the guide was fully post-cured in a cure chamber. Supports were removed, and a stainless steel guide tube that coincides with the Zimmer Size A keys was inserted into the resin guide hole to complete the guide fabrication.

Finally, the guide was bagged and autoclave sterilized to prepare it for the procedure.

Fig. 5: The surgical guide was printed with Dental SG on a Form 2, rinsed in IPA, fully post-cured, finished, assembled with a metal guide sleeve, and sterilized prior to intraoperative use.



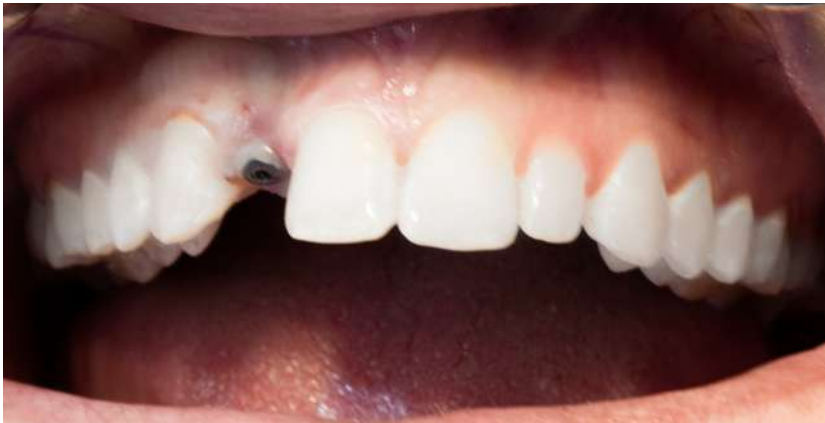

CLINICAL PROCEDURE

The patient began a regimen of 500mg of Azithromycin starting the day before surgery and continuing for three days. On the day of surgery, the patient performed a pre-op rinse with Chlorhexidine Gluconate 0.12% for 1 minute and was then draped accordingly in preparation for the implant procedure. 1 carpule of 4% septocaine 1:100k epi and 1 carpule of 2% lidocaine 1:50k epi were infiltrated into the #7 area facially and palatally.

The guide was tried in the patient's mouth to ensure proper fit and stability, and the tissue was punched in the designated location based on the guide tube. The appropriate Zimmer Size A key in sequence with the 2.85 mm x 22 mm drill was used with copious irrigation (.9% sodium chloride) to perform the osteotomy.

Fig. 6: Post-Operative Examination indicated positive results. A post-operative CBCT scan was then taken to verify planned vs. final implant placement.



Afterwards, the guide was removed and the osteotomy irrigated and inspected to ensure that there were no fenestrations or dehiscences in the osseous structures. The osteotomy was fully in bone, so the implant was installed using the implant handpiece at a 30 Ncm torque. Final placement was completed by hand-using the manual torque wrench, achieving good primary stability at around 35 Ncm. A periapical image was then taken to confirm that the implant was fully installed in the osteotomy.

A custom healing abutment was created using the Zimmer temporary abutment and bis-acryl temporary material. This was shaped accordingly and installed into the implant with finger tightness (~ 15 Ncm). Next, a postoperative CBCT was taken with the Sirona Orthophos XG 3D (Sirona Dental; Bensheim, Germany). Finally, the patient had been wearing a Hawley retainer with a denture tooth in the #7 location since completion of orthodontics. The retainer was tried in, and the intaglio surface was relieved to reduce pressure on the implant site. Postoperative instructions were given, and the patient was released.

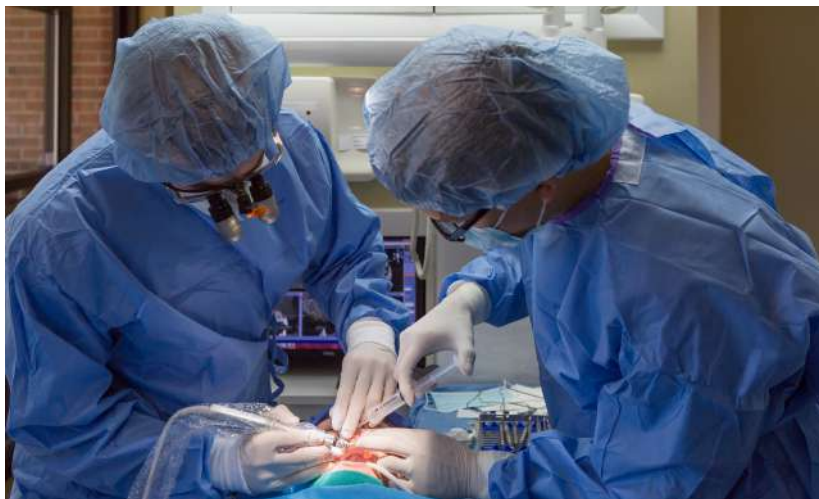

Fig. 7: Dr. Whitley and Dr. Bencharit performing the osteotomy.

Discussion

To evaluate clinical outcomes of the dental implant procedure, we compared the presurgical plan to the actual final implant placement. The postoperative CBCT scan was imported into the original plan in Blue Sky Bio. The density of the scan was adjusted appropriately to show the implant in one window and the teeth in the other. This allowed for superimposition of the two scans by matching common points on teeth.

Analysis of the deviation between original planned and final implant placement throughout the slices revealed a very accurate placement. Due to the scattering effect of metal in the CBCT image, the exact deviation was difficult to qualify. A maximum deviation of implant position at the entrance point was measured to be 0.23 mm (see Fig. 8). A maximum deviation of 2.5° along the long axis of the implant was measured. The apical measurements were not taken due to distortion in the image from the screw vent in the fixture and no screw vent in the virtual implant cylinder.

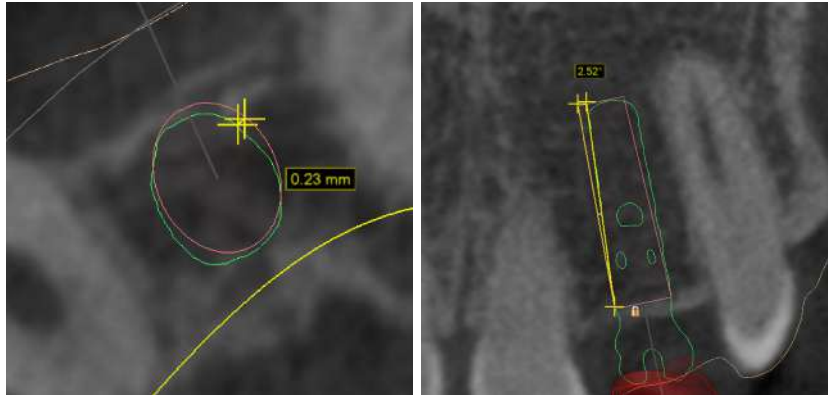


Fig. 8: Planned (red) vs actual (green) implant placement (left) and angulation (right).

The final accuracy of the implant placement fell well within the expected bounds of most clinical trials for CAD/CAM guided surgeries conducted with commercially available industrial 3D printing systems^{4,9}.

Sources of Error in Manufacturing CAD/CAM Surgical Guides:

- Intraoral scan accuracy
- CBCT scan accuracy
- Implant planning software accuracy
- Printer accuracy
- Dimensional tolerances of drill bit and guide sleeve
- Human error
- Patient movement

AVERAGE PLANNED VS. ACTUAL DEVIATION

SURGICAL TECHNIQUE	IMPLANT POSITION AT ENTRANCE (MM)	ANGULATION
Freehand ⁵	2.0 – 2.5	No data
Traditionally manufactured fully-limited guide ²	1.5	8°
CAD/CAM fully-limited guide ⁴	0.9 – 1.0	5°
Study guide	0.23	2.5°

To study the amount of final error attributable to the printer, the actual printed guide used in the surgery was compared to the .STL model of the surgical guide generated in implant treatment planning software. Superposition of the planned and actual model indicated that the position of the guide hole had a maximum deviation of 0.1 mm. Therefore, we conclude that out of the 0.23 mm maximum deviation in implant position at the entrance point, a maximum of 0.1 mm was attributable to the printing of the guide on the Form 2. The remaining error was propagated by additional sources of error.

Most importantly, the accuracy of the implant placement was high enough to be of no clinical significance, and there were good clinical outcomes for the patient. The postoperative CBCT showed that we were able to maintain good facial bone thickness and appropriate depth of placement.

In addition, using the guide significantly decreased procedure time, eliminating flap advancement, drill angle determination, and tissue reapproximation. This turned a traditionally 60-minute-long procedure into only a 20-minute procedure.

Conclusion

Traditionally, high surgical guide fabrication costs have been a barrier to use. Typically it has been necessary to export the guide plan to a dental laboratory or off site for final guide design and fabrication, costing \$250 – \$500 depending on the laboratory and complexity of the case.

By using the Form 2 and free implant planning software, the results clearly demonstrate a workflow that produces accurate surgical guides at a significantly lower cost. Compared to 3D printing systems currently favored in the dental industry that cost upwards of \$25,000, the \$3,500 cost of the Form 2 lowers the barrier to entry by a significant margin. It not only provides the potential for improving accessibility to additive manufacturing for smaller dental laboratories, but also, for the first time ever, dental practices of all sizes.

Surgical guides can also be produced at an extremely affordable variable cost: in our clinical study, the variable cost of producing the surgical guide was only \$5.13.

SURGICAL GUIDE MATERIAL COSTS

ITEM	COST
Dental SG Resin (11 mL)	\$4.39
Resin tank use (per guide cost)	\$0.74*
Total variable costs of guide production	\$5.13

*Estimated by dividing resin tank cost (\$59) by a print volume of 80 guides per resin tank.

Most importantly, this workflow establishes low-cost surgical guide production methods without a trade-off in quality. The clinical case demonstrated the ability to place an implant with accurate final placement that is well within the tolerances that previous dental 3D printing systems can achieve, resulting in extremely good clinical outcomes for the patient.

References

1. Kola MZ, Shah AH, Khalil HS, Rahah AM, Harby NMH, Sabra SA, Raghav D: Surgical templates for dental implant positioning; current knowledge and clinical perspectives. *Niger J Surg* 21(1):1 – 5, 2015
2. Sarment, DP, Sukovic, P, Clinthorne, N. Accuracy of implant placement with a stereolithographic surgical guide. *Int J Oral Maxillofac Implants. Inter J Oral Maxillofacial Implants* 28 M18(4):571 – 577, 2003
3. Greenberg A: Digital technologies for dental implant treatment planning and guided surgery. *Oral Maxillofacial Surg Clin N Am* 27:319 – 340, 2015
4. Nickenig HJ, Eitner S, Rothamel D, Wichmann M, Zoller JE: Possibilities and limitations of implant placement by virtual planning data and surgical guide templates. *International Journal of Computerized Dentistry* 15(1): 9 – 21, 2012
5. Arisan V, Karabuda CZ, Mumcu E, Ozdemir T: Implant positioning errors in freehand and computer-aided placement methods: a single blind clinical comparative study. *Inter J Oral Maxillofacial Implants* 28(1):190 – 204, 2013
6. Greenstein G, Cavallaro J, Romanos G, Tarnow D: Clinical recommendations for avoiding and managing surgical complications associated with implant dentistry: a review. *J Periodontol* 79(8):1317 – 1329, 2008
7. D'Souza KM, Aras MA: Types of implant surgical guides in dentistry: a review. *J Oral Implantology* 38(5):643 – 652, 2012
8. Torabi K, Farjood E, Hamedani S: Rapid prototyping technologies and their applications in prosthodontics, a review of literature. *J Dent Shiraz Univ Med Sci* 16(1):1 – 9, 2015
9. Gallardo Y, Silva-Olivio IRT, Mukai E, Morimoto S, Sesma N, Cordaro L: Accuracy comparison of guided surgery for dental implants according to the tissue of support: a systematic review and meta-analysis. *Clin Oral Implants Research* 0: 1 – 11, 2016